Cardiac Transplantation in Situs Inversus: Two Cases Reports

Y.L. Chang, J. Wei, C.-Y. Chang, Y.-C. Chuang, and S.-H. Sue

ABSTRACT

The challenge of heart transplantation in patients with situs inversus is reconstruction of the systemic venous return. Herein we have presented 2 cases of complex congenital heart disease with atriovisceral situs inversus. Both of the patients shared many common cardiac anomalies, such as a single ventricle, a single AV valve with severe regurgitation, and severe pulmonary stenosis. We completed the venous connection in 2 different ways. In the first case, the donor inferior vena cava (IVC) was anastomosed to the recipient left-sided IVC directly, making the heart slightly counterclockwise rotated. In the second case, the IVC venous reconnection was accomplished by a composite conduit made of recipient right atrium.

HEART transplantation is one therapeutic option for complex congenital heart disease. In patients with situs inversus, the challenge of heart transplantation is reconstruction of the systemic venous return.[1–4] The left-sided original vena cava has to be rerouted to the right-sided donor conduit. To earn more space for the inferior vena cavae (IVC) reconstruction, the choice of the site of venous cannulation is important. Herein we have presented 2 cases of complex congenital heart disease with atriovisceral situs inversus. Both patients developed heart failure in adolescence: 1 patient was 18 and the other patient was 16 years old. Both subjects shared many common cardiac anomalies, such as a single ventricle, a single atrioventricular valve with severe regurgitation, and severe pulmonary stenosis. Except for the bilateral superior vena cava (SVC) in the first patient, their diagnoses were almost the same. We completed the venous connection in 2 different ways.

CASE REPORT 1

An 18-year-old woman had been diagnosed with situs inversus of the viscera and atrium as well as complex congenital heart disease since birth. The anomalies included a single ventricle with dextrocadia, a transposition of great arteries (d-TGA), severe valvular pulmonary stenosis, a ltlift aortic arch, and bilateral SVC. She had undergone a modified Blalock-Taussig shunt created over the right pulmonary artery when she was about 1 year old. It was not until exertional dyspnea, cyanotic lips, and lower leg edema developed for 3 months that she went to a local hospital for case 1care. Under the impression of a gradually stenotic shunt and congestive heart failure, she was referred to our hospital for heart transplantation.

The preoperative EKG revealed normal sinus rhythm. All laboratory data were within normal limits except the hematocrit level was 58% and the room air oxygen saturation was 90%. Echocardiography disclosed a moderate pericardial effusion, globally impaired ventricular function, and a complex congenital malformation, which included situs inversus of the atria with the apex to the right. Bilateral SVC individually joined into a left-sided right atrium. Both atria connected to a single morphological left ventricle. The aorta was located anterior and to the right of the pulmonary artery. The main pulmonary artery displayed significant valvular stenosis. A modified Blalock-Taussig shunt created over the right pulmonary artery was patent with stenotic turbulence. The aorta descended in the left side of the spine. The cardiopulmonary function test showed MVO_2/kg to be 12.7 mL/kg/min. The abdominal sonogram showed visceral situs inversus, splenomegaly, bilateral symmetric liver, and ascites. A suitable donor was located on November 5, 2005. The patient underwent emergency orthotopic heart transplantation.

Procurement of Donor Heart

The donor heart was excised using the standard procedure. To obtain sufficient tissue for a systemic venous reconstruction, the full length of SVC and innominate vein were retained with the heart. The aortic arch was harvested along with the heart. The excessive tissue between the orifices of the 4 pulmonary veins was incised as usual. The left atrium was cut into a proper size. The right atrium was not opened because systemic venous reconstruction would be accomplished by direct vena cavae anastomoses.

Receipient Operation

Via a Median sternotomy 1 arterial line was built over the ascending aorta. Venous drainage was established by 2 cannulae. The upper venous cannula was inserted into the left SVC. To earn more space for IVC reconstruction, the lower 1 was cannulated in

From the Heart Center, Cheng-Hsin General Hospital, Taipei, Taiwan, R.O.C.

Address reprint requests to Jeng Wei, MD, MSD, Heart Center, Cheng-Hsin General Hospital, 45 Cheng-Hsin Street, Taipei, 112, Taiwan, R.O.C. E-mail: jengwei@mac.com

0041-1345/08/$–see front matter
doi:10.1016/j.transproceed.2008.07.115

the left femoral vein. The IVC was snared and the aorta cross-clamped. The recipient heart was removed. The recipient's morphological right atrium was then converted into a tunnel by suturing the free wall of right atrium to the atrial septum. With the heart positioned like a mesocardia, transplantation was started by connecting the donor left atrium to the recipient left atrium. After the atrial anastomosis was accomplished, the donor IVC was connected to the recipient IVC directly. The left pleura was incised to allow the apex to rotate into the left pleural space. The patient had bilateral SVC. At first, we connected the donor SVC to the recipient right SVC and ligated the left SVC. The aortaelosses of donor and recipient were anastomosed end-to-end, as were the pulmonary arteries. After the aorta was declamped, engorgement of the left SVC was noted. Due to the suspicion of poor venous return, we used a 12-mm Dacron graft to create a shunt between the left SVC and the IVC (Fig 1). Unfortunately, low cardiac output developed. Therefore, we inserted an extracorporeal membrane oxygenation (ECMO) system and vented the left ventricular through the aorta and left femoral vein. Intraaortic balloon pumping (IABP) was inserted through the right femoral artery. Despite a smooth operative procedure, it took us many hours to control the bleeding.

After transplantation, the hemodynamics gradually became stable. Both IABP and ECMO were removed on postoperative day 3 followed by extubation from the ventilator. Left ventricular ejection fraction up to 55% was observed on echocardiography. On postoperative day 6, the patient was ambulatory. Two days later, she suddenly collapsed while eating. Despite reintervention of ECMO and IABP, the patient died on postoperative day 33.

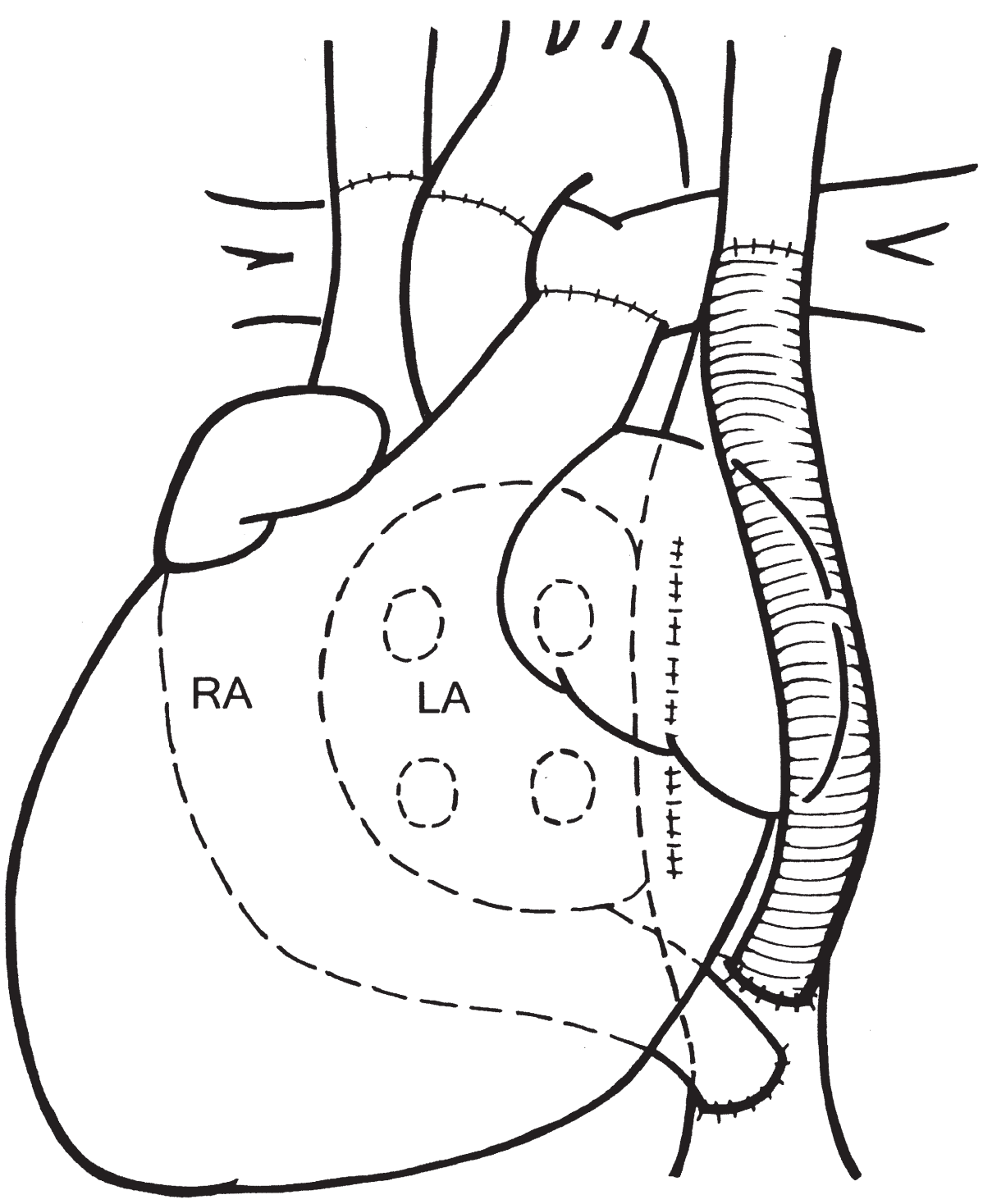

Fig 1. In case 1, the donor SVC was connected to the recipient right SVC. The donor IVC was anastomosed to recipient IVC directly. Then venous return from donor left SVC was rerouted by a 12-mm Dacron graft to IVC.

Fig 2. The original heart of case 2.

CASE REPORT 2

A 16-year-old boy was referred for intractable paroxysmal supraventricular tachycardia (PSVT) and ventricular dysfunction. He was known to have situs inversus and complex congenital heart disease since birth. The anomalies included mesocardia, d-TGA, a single ventricle, a common atrio-ventricular valve with severe regurgitation, a subpulmonary stenosis, and a right aortic arch (Fig 2). The physical examination revealed clubbing of the fingers, cyanotic lips, and a loud heart murmur throughout both systole and diastole. All laboratory data were within normal limits except the hematocrit level was 52% and the PaO_2 was 80 mm Hg. Because of frequent attacks of PSVT and poor heart function during the past half year, he became increasingly limited and was placed on the transplant waiting list.

During 1 episode of PSVT, he was sent to our emergency room on August 15, 2006. Although the heart rhythm had been successfully reversed into sinus rhythm with medicine, profound shock occurred, followed by hepatic failure and renal failure. An ECMO was implanted to correct the low cardiac output. Within 1 week, the heart regained its viability and the boy's consciousness returned. Subsequently, we failed every time we tried to wean him off the ECMO. During this period, he developed septicemia, fungemia, renal failure, and hepatic failure. It was not until 3 weeks later that we located a suitable donor. The technique of donor heart procurement was the same as the first case, but we implanted the heart a different way.

Recipient Operation

We instituted cardiopulmonary bypass through the ascending aorta, left femoral vein, and left SVC. After the IVC was snared and the aorta cross-clamped, the recipient heart was removed along the AV groove. Both atria were cut into proper size. The morphological right atrium was trapped into a tunnel connecting the systemic venous return. We took 1 piece of discarded atrial-free wall, wrapped it, and converted it into a conduit that was 4 cm in diameter and was used as a bridge of the donor IVC to the recipient IVC (Fig 3). Heart implantation was begun with a left atrial anastomosis, followed by IVC connection to the conduit, then the pulmonary artery anastomosis, and the aortic anastomosis. The donor's innominate vein was connected to the recipient SVC in an end-to-side manner. Due to the limited length, the innominate vein lay between the aorta and the main pulmonary artery. We interposed a titanic ring to avoid compression of the vein (Fig 4). With these anastomoses, the heart sat in the mediastinum in the normal left-sided position.

ECMO was weaned off on the operative day. With the aid of hemodialysis and Molecular Adsorbent Recirculating System (MARS, Teraklin GmbH, Rostock, Germany), renal and hepatic function recovered gradually over the following days. Creatinine level decreased from 5.3 to 1.1 mg/dL, total bilirubin reduced from 34 to 2.3 mg/dL, ammonia decreased from 85 to 25 mg/dL. The patient was in excellent condition. Unfortunately, on the 12th postoperative day, he suddenly developed a seizure and lost consciousness. Brain computed tomography (CT) showed a large territory left middle cerebral artery hemorrhagic infarction. Although we performed emergency craniotomy to remove the hematoma, the patient never regained consciousness. He died 2 weeks later with good heart function. The cause of brain hemorrhage was a septic embolus seeded during the fungemia before heart transplantation. Total survival was 24 days.

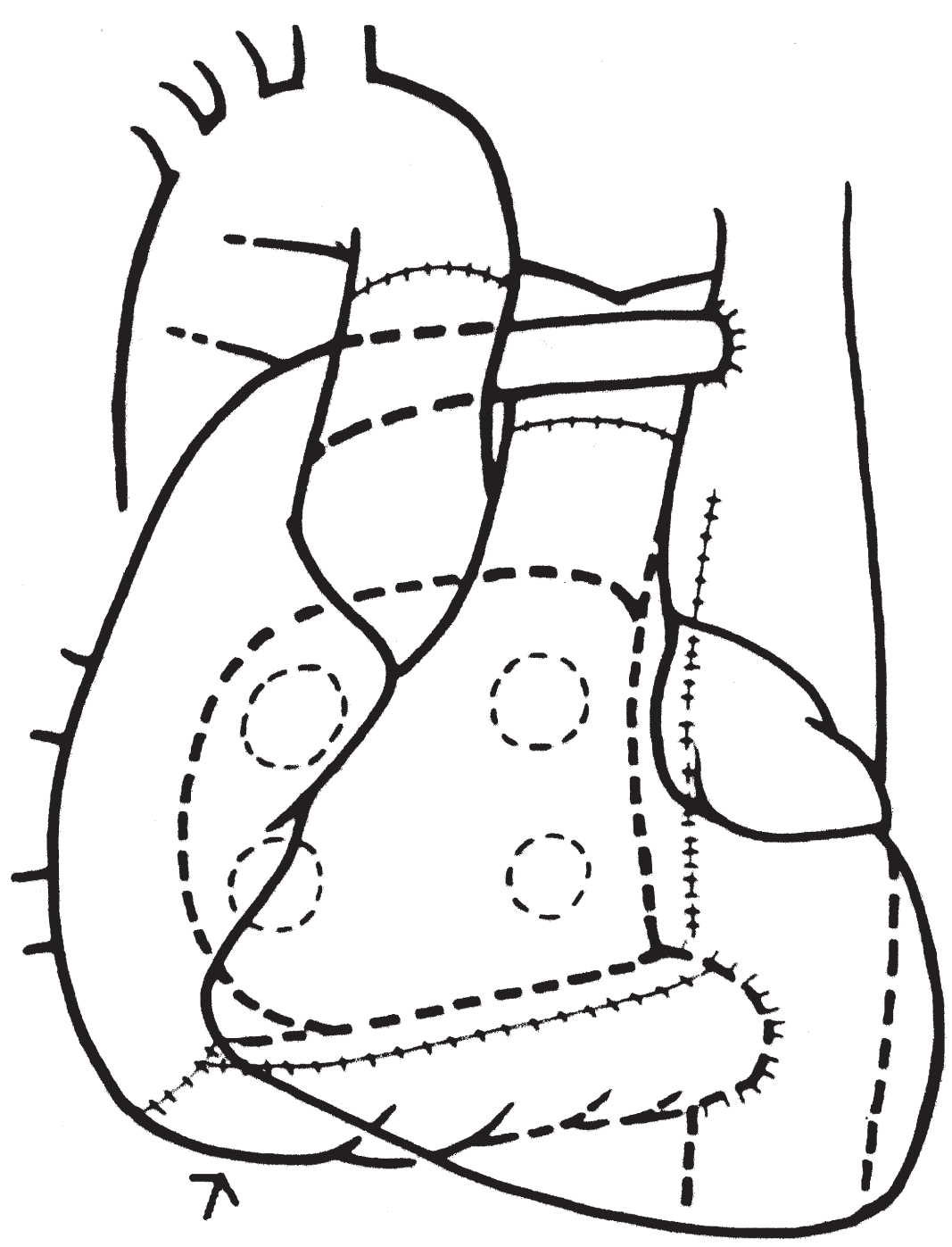

Fig 3. In case 2, the donor innominate vein was connected to the recipient SVC directly. A piece of RA-free wall was enrolled into a conduit (pointed by the black arrow), served as a bridge between donor and recipient IVCs.

Fig 4. Due to limited length, the innominate vein lay between the aorta and the main pulmonary vein. We put a titanic ring to protect the innominate vein from external compression.

DISCUSSION

Reconstruction of the mirror image systemic and pulmonary venous pathways remains the essence of cardiac transplantation in situs inversus patients. According to the previous literature, many authors have described a variety of extracardiac and intracardiac channels to correct the venous return. Doty et al used an incised pericardium and part of the diaphragm to reroute the IVC venous return back to the donor heart[1] Rubay et al used an aortic homograft to create a composite conduit between donor and recipient SVCs.[4] Some authors created 2 intracardiac baffles from left-sided atrial tissue and rerouted the SVC and IVC back to the donor right atrium.[5] In our first case, we used the method of Cooper et al to connect the donor and recipient IVC directly, giving the heart a bit of a counterclockwise rotation,[2] which was the possible reason for the patient to develop a heart twist and the sudden onset of shock at the first ambulation.

In our second case, we used an extended length of donor innominate vein to connect to the recipient SVC. Being afraid of external compression by the pulmonary artery, we used a titanic ring to protect the vein. In addition, we took a piece of right atrium-free wall, rolling it into a composite tubular graft. The autogenous conduit served as a bridge between donor and recipient IVC, thus allowing the heart to be placed in a normal left-sided position. The vascular endothelial surface of the RA-free wall conduit was superior to a prosthetic graft.[5] Although long-term patency could not be observed, the autogenous conduit is still be our choice for the next patient.

In conclusion, situs inversus and a single ventricle in patients with cardiac transplantation remains exceptionally rare.[6] This subset of patients represents a small group of candidates. Using a conduit made of autogenous RA-free wall may solve the problem of venous reconstruction. Careful preoperative planning may shorten the operative time and achieve success.

REFERENCES

1. Doty DB, Renlund DG, Caputo GR, et al: Cardiac transplantation in situs inversus. J Thorac Cardiovasc Surg 99:493, 1990

2. Cooper DKC, Ye Y, Chaffin JS, et al: A surgical technique for "orthotopic" heart with situs inversus. J Thorac Cardiovasc Surg 116:82, 1998

3. Vricella LA, Razzouk AJ, Gundry SR, et al: Heart transplantation in infants and children with situs inversus. J Thorac Cardiovasc Surg 116:82, 1998

4. Rubay JE, d'Udekem Y, Sluymans T, et al: Orthotopic heart transplantation in situs inversus. Ann Thorac Surg 60:460, 1995

5. Michler RE, Sandhu AA: Novel approach for orthotopic heart transplantation in visceroatrial situs inversus. Ann Thorac Surg 60:194, 1995

6. Berdat PA, Mohacsi P, Althuas U, et al: Successful heart transplantation in a patient with Ivemark syndrome combined with situs in versus, single atrium and ventricle after total cavo-pumonary connection. Eur J Cardio-Thorac Surg 14:631, 1998